Latin American Journal of Pharmacy
(formerly *Acta Farmacéutica Bonaerense)*
Lat. Am. J. Pharm. **37** (6): 1089-96 (2018)

Received: January 22, 2018
Revised version: April 15, 2018
Accepted: April 16, 2018

Potential Anti-Oxidant and Anti-Inflammatory Effects of Losartan Against Thioacetamide-Induced Hepatic Damage in Rats

Rasha E. MOSTAFA

Department of Pharmacology and Toxicology,
College of pharmacy, Taif University, KSA

Pharmacology Department, Medical Division, National Research Centre, Giza, Egypt.

***SUMMARY*. The present study was designed to test the potential protective effect of losartan, an angiotensin II receptor blocker, on amelioration of hepatic damage induced experimentally in rats via thioacetamide (TAA) administration. Rats were divided into 4 groups. Group 1 received only saline. Group 2 received only TAA (300 mg/kg, IP). Groups 3 and 4 received TAA, followed by silymarin (100 mg/kg, P.O) or losartan (5 mg/kg, P.O) respectively for 30 days. Serum & liver samples were obtained for biochemical analyses. Histological examinations were also done. TAA administration caused severe deterioration in all liver function tests, oxidative stress parameters, inflammatory markers as well as histopathological picture. Losartan administration resulted in improvement of the aforementioned parameters as well as histopathological picture when compared to TAA-control group. These results were comparable to those of silymarin. In conclusion, losartan ameliorated TAA-induced hepatic damage in rats; this effect was attributed to its anti-oxidant and anti-inflammatory properties.**

RESUMEN. El presente estudio fue diseñado para evaluar el efecto protector potencial del losartán, un bloqueador del receptor de la angiotensina II, sobre la mejora del daño hepático inducido experimentalmente en ratas a través de la administración de tioacetamida (TAA). Las ratas se dividieron en 4 grupos. El grupo 1 recibió solo solución salina. El grupo 2 recibió solo TAA (300 mg/kg, IP). Los grupos 3 y 4 recibieron TAA, seguido de silimarina (100 mg/kg, P.O) o losartán (5 mg/kg, P.O.) respectivamente durante 30 días. Se obtuvieron muestras de suero e hígado para análisis bioquímicos. También se hicieron exámenes histológicos. La administración de TAA causó un deterioro severo en todas las pruebas de función hepática, parámetros de estrés oxidativo, marcadores inflamatorios e imagen histopatológica. La administración de losartán dio lugar a una mejoría de los parámetros mencionados anteriormente, así como a una mejor imagen histopatológica en comparación con el grupo control TAA. Estos resultados fueron comparables a los de la silimarina. En conclusión, el losartán mejoró el daño hepático inducido por TAA en ratas, efecto atribuible a sus propiedades antioxidantes y antiinflamatorias.

INTRODUCTION

Liver diseases pose a hugely overspread worldwide problem since they are commonly associated with substantial morbidity and mortality. Hepatic toxicity presents a broad spectrum of diseases; with hepatitis being the most common clinical presentation [1]. However, all types of hepatic damage can occur, ranging from apoptosis, necrosis to fibrosis and cirrhosis. Hepatocyte death is the main feature of hepatic damage. Gradual replacement with scar tissue usually occurs following hepatocyte death [2]. This leads to impairment of blood flow through the hepatic tissue causing further hepatocyte death and loss of liver function. Apoptotic and inflammatory responses start to form following these events [3]. This is further accompanied by poor regeneration of dying cells and accumulation of fibrillar collagen [4]. In response to hepatic injury, specific intracellular processes are initiated to sustain hepatic integrity. Inflammatory cytokines, including tumor necrosis factor alpha (TNF-α), Transforming growth factor- beta1 (TGF-β1), interleukin-1 beta (IL-1β) and interleukin-6 (IL-6) are the main mediators that initiate and maintain cellular changes leading even-

KEY WORDS: hepatic damage, inflammation, losartan, oxidative stress, rats, thioacetamide.

* Author to whom correspondence should be addressed. *E-mail:* dr_rosha81@yahoo.com

ISSN 0326 2383 (printed ed.)
ISSN 2362-3853 (on line ed.)

tually to cellular death [5]. Apoptotic markers as p53, caspase-3, caspase-9 and Bcl-2 are significantly expressed leading to activation of different cellular response [6]. Furthermore, liver exposure to reactive oxygen species (ROS) and nitrogen species, especially when accompanied by significant reduction in protective anti-oxidant balance leads to severe disruption of cellular functions through lipid peroxidation [7,8]. Lipid peroxidation then activates multiple cytotoxicity pathways eventually leading to the initiation of inflammatory cascade [9,10]. Thioacetamide (TAA) is a potent selective hepatotoxin causing centrilobular necrosis. TAA administration causes induction of apoptosis, inflammation, hepatic necrosis as well as oxidative damage in rat liver [11,12].

Silymarin is mixture of flavonoid isomers extracted from *Silybum marianum,* also known as milk thistle [13]. Silymarin is a well-known hepato-protective agent used in treatment of hepatic injuries originating from various origins such as alcoholic, viral or drug- induced [14]. Silymarin mainly exerts its actions via scavenging of free radicals and enhancement of anti-oxidant defense mechanisms. Silymarin also exhibits anti-inflammatory as well as anti-metastatic properties [15,16].

Losartan (2-N-butyl-4-chloro-5-hydroxymethyl-1-[(2'-(1H-tetrazol-5-yl)biphenyl-4-yl) methyl]imidazole) is a typical angiotensin II type I receptor (AT_1R) blocker commonly used in control of elevated arterial blood pressure. This can be attributed to the ability of angiotensin II to elevate vascular permeability, enhance inflammatory response and initiate pro-inflammatory cytokines and chemokines [17]. Losartan among other AT_1R blockers has protective effects in various experimental hepatic ischemia/reperfusion (I/R) models [18,19]. Losartan successfully ameliorated hepatic I/R injury via inhibition of hepatic apoptosis, neutrophil infiltration and intercellular adhesion molecule-1 expression [20]. It has also been proposed that activated hepatic stellate cells (HSCs) might overexpress AT_1R during fibrosis [21]. Increasing evidence suggests that many angiotensin receptor blockers (ARBs) possess partial agonistic affinities towards peroxisome proliferator-activated receptor- gamma (PPAR-γ) [22-24]. ARBs inhibit LPS-induced pro-inflammatory response through PPAR-γ activation in human monocytes [25]. Moreover, ARBs have been found to decrease oxidative damage and restore blood flow in ischemic heart regions through PPAR-γ pathway activation [26].

Therefore, the present study is designed to test the potential protective effect of losartan; an AT_1R blocker, on amelioration of hepatic inflammation and oxidative stress damage induced experimentally in rats via TAA administration. The study also compares the potential hepato-protective effects of losartan against hepato-protective effects of silymarin.

MATERIALS AND METHODS

Animals

Adult male Wistar rats, weighing 130-150 g body weight were used. The animals were obtained from the Animal House Colony of National Research Centre (Dokki, Giza, Egypt) and were housed under conventional laboratory conditions throughout the period of the experimentation. Animals were provided with standard laboratory food pellets and tap water *ad libitum*. The study was conducted in accordance with the National Research Centre- Medical Research Ethics Committee (NRC-MREC) for the use of animal subjects and following the recommendations of the National Institutes of Health Guide for Care and Use of Laboratory Animals.

Chemicals

TAA was obtained from Sigma (St. Louis, MO, USA). TAA was prepared freshly by dissolving in saline and stirred well until all crystals were dissolved. Losartan (Cozaar®, 50 mg tablets; Merck & Co., Inc, USA) and silymarin (Legalon®, 70 mg sugar-coated tablets; Madaus Gmbh, Köln, Germany) were used in the study. All other chemicals used throughout the experiment were of the highest analytical grade available.

Experimental protocols

Forty rats were divided into four groups, 10 animals each. Group 1 received only saline and served as normal control group. Group 2 received only thioacetamide (TAA; 300 mg/kg, IP) and served as TAA-control group. Groups 3 and 4 received TAA (300 mg/kg, IP), followed by daily silymarin (100 mg/kg, P.O) and losartan (5 mg/kg, P.O) respectively for 30 days. Animals received dextrose water and ringer lactate solutions (10 mg/kg/day, i.p.) to prevent renal failure, hypoglycemia and electrolyte imbalance till the end of the experiment [27]. All rats were sacri-

ficed under anesthesia twenty-four hours after the last treatment and overnight fasting.

Preparing serum and tissue homogenates

Before sacrifice, blood samples were collected from the retro-orbital vein plexuses under light ether anesthesia. Collected blood samples were allowed to stand for 10 min at room temperature then centrifuged at 4 °C using cooling centrifuge (Laborezentrifugen, 2k15, Sigma, Germany) at 3000 rpm for 10 min and sera were separated.

After sacrifice, the livers were extracted and washed three times with ice-cold physiological saline (0.9% NaCl). Parts of the livers were frozen immediately at -80 °C for further investigation. The other parts of the livers were fixed in 10% neutral buffered formaldehyde for histopathologic examinations.

Hepatic biochemical parameters in serum

Serum samples were used for the biochemical analyses of aspartate transaminase (AST) & alanine transaminase (ALT) [28], alkaline phosphatase (ALP) activites [29], total bilirubin [30] and total protein [31] levels using commercially available kits according to the manufacturer's instructions (Biodiagnostics, Egypt).

Hepatic Tissue biochemical analysis

Parts from livers were homogenized (MPW-120 homogenizer, Med instruments, Poland) to obtain 20% homogenate that was stored overnight at -20°C. The homogenates were centrifuged for 5 min at 5000 × *g* using a cooling centrifuge (Sigma and Laborzentrifugen, 2k15, Germany). the supernatant was assessed for hepatic levels of reduced glutathione (GSH) [32], lipid peroxides as malondialdehyde (MDA) [33], and nitric oxide (NOx) metabolites [34] using commercially available kits according to the manufacturer's instructions (Biodiagnostics, Egypt). Inflammatory markers such as myeloperoxidase (MPO) [35], interleukin-1β (IL-1β) [36] and tumor necrosis factor-alpha (TNF-α) [37] were assessed using enzyme-linked immunosorbent assay (ELISA) kits (Hycult Biotech, Netherlands) and (R&D Systems, USA), respectively, according to the manufacturer's instructions.

Histopathological study

The liver tissues were fixed in 10% formalin and then embedded in paraffin, cut into 5 mm thick sections, stained with hematoxylin and eosin (H&E), and then examined by an experienced pathologist under binocular Olympus CX31 microscope [38].

Statistical analysis

All results are expressed as Means ± SE. Multiple group comparisons were performed by analysis of variance (ANOVA) followed by Tukey's multiple comparisons post hoc test. Difference was considered significant when $p < 0.05$. SPSS® software (version 17.00 for Windows, Chicago, USA) was used to carry out these statistical tests.

RESULTS

Effects on serum biochemical parameters

Administration of TAA was associated with marked increase in serum activities of AST, ALT and ALP to 857, 743, and 223 %, respectively. Total bilirubin concentration was increased to 403% whilst total protein concentration was decreased to 6% as compared to normal control group.

Silymarin treatment (100 mg/kg) significantly decreased serum AST, ALT and ALP activities to 52, 60, and 70%, respectively. Moreover, siymarin caused reduction of the elevated total bilirubin concentration to 58% and elevation of the reduced total protein concentration to 1063% as compared to TAA-control group.

Losartan treatment (5 mg/kg) significantly decreased serum AST, ALT and ALP activities to 48, 56, and 66%, respectively. Moreover, losartan caused reduction of the elevated total bilirubin concentration to 50% and elevation of the reduced total protein concentration to 960% as compared to TAA-control group. The effects of losartan and silymarin at the selected doses were not significantly different ($P < 0.05$, Table 1).

Effect on oxidative stress parameters in hepatic tissues

Administration of TAA was associated with significant decrease in hepatic GSH concentration to 30% and significant increase in hepatic concentration of MDA and NOx metabolites to 242 and 197 %, respectively, as compared to normal control group.

Silymarin treatment (100 mg/kg) significantly increased hepatic GSH concentration to 181% and decreased hepatic concentration of MDA and NOx to 75 and 78%, respectively, as compared to TAA-control group.

	Parameters	AST (IU/L)	ALT (IU/L)	ALP (IU/L)	Total Bilirubin (mg/dL)	Total protein (g/dL)
Groups	Normal Control	35.20 ± 1.26	29.13 ± 1.32	95.72 ± 5.05	0.46 ± 0.02	10.03 ± 0.38
	TAA-Control (300 mg/kg, i.p.)	301.73[a] ± 0.78	216.54[a] ± 10.73	213.00[a] ± 9.74	1.87[a] ± 0.07	0.58[a] ± 0.01
	TAA + Silymarin (100 mg/kg, p.o.)	157.60[a,b] ± 4.52	130.87[a,b] ± 9.49	150.10[a,b] ± 6.44	1.09[a,b] ± 0.05	6.22[a,b] ± 0.48
	TAA + Losartan (5 mg/kg, p.o.)	143.47[a,b] ± 6.12	122.33[a,b] ± 7.09	139.77[a,b] ± 1.17	0.94[a,b] ± 0.03	5.61[a,b] ± 0.49

Table 1. Effects of losartan (5 mg/kg) and silymarin (100 mg/kg) on serum biochemical parameters; aspartate transaminase (AST) activity, alanine transaminase (ALT) activity, alkaline phosphatase (ALP) activity, total bilirubin concentration and total protein concentration; in thioacetamide-induced hepatic damage in rats. Rats of the normal control group received only saline. Hepatic damage was induced in the remaining 3 groups by single intraperitoneal injection of thioacetamide (TAA; 300 mg/kg). Group 2 received only thioacetamide (TAA; 300 mg/kg, i.p.) and served as TAA-control group. Groups 3 and 4 received TAA, followed by daily silymarin (100 mg/kg, p.o.) and losartan (5 mg/kg, p.o.) respectively for 30 days. Blood samples were collected and sera were separated. Data is presented as mean ± SEM (n = 10). [a] Significantly different from normal control group at $p < 0.05$ (Tukey's post hoc test). [b] Significantly different from TAA-control group at $p < 0.05$ (Tukey's post hoc test).

	Parameters	GSH (µmol/g tissue)	MDA (nmol/g tissue)	NOx (µmol/g tissue)
Groups	Normal Control	2.74 ± 0.07	24.95 ± 1.54	138.43 ± 5.81
	TAA-Control (300 mg/kg, i.p.)	0.83[a] ± 0.05	60.37[a] ± 1.13	272.85[a] ± 7.21
	TAA + Silymarin (100 mg/kg, p.o.)	1.49[a,b] ± 0.10	45.02[a,b] ± 1.27	213.20[a,b] ± 6.36
	TAA + Losartan (5 mg/kg, p.o.)	1.37[a,b] ±0.03	47.44[a,b] ± 2.35	216.08[a,b] ± 5.04

Table 2. Effects of losartan (5 mg/kg) and silymarin (100 mg/kg) on hepatic tissue oxidative stress parameters; reduced glutathione (GSH), malondialdehyde (MDA) and nitric oxide (NOx) metabolites; in thioacetamide-induced hepatic damage in rats. Rats of the normal control group received only saline. Hepatic damage was induced in the remaining 3 groups by single intraperitoneal injection of thioacetamide (TAA; 300 mg/kg). Group 2 received only thioacetamide (TAA; 300 mg/kg, i.p.) and served as TAA-control group. Groups 3 and 4 received TAA, followed by daily silymarin (100 mg/kg, p.o.) and losartan (5 mg/kg, p.o.) respectively for 30 days. All animals were sacrificed 24 h after the last treatment. The livers were removed, homogenized and the homogenate was obtained. Data is presented as mean ± SEM (n = 10). [a] Significantly different from normal control group at $p < 0.05$ (Tukey's post hoc test). [b] Significantly different from TAA-control group at $p < 0.05$ (Tukey's post hoc test).

Losartan treatment (5 mg/kg) significantly increased hepatic GSH concentration to 166% and decreased hepatic concentration of MDA and NOx to 79 and 79%, respectively, as compared to TAA-control group. The effects of losartan and silymarin at the selected doses were not significantly different ($P < 0.05$, Table 2).

Effect on inflammatory parameters and cytokines in hepatic tissues

Administration of TAA was associated with significant increase in hepatic tissue MPO activity as well as hepatic concentration of IL-1β and TNF-α to 1056, 805, and 382 %, respectively, as compared to normal control group.

Silymarin treatment (100 mg/kg) significantly decreased hepatic tissue MPO activity as well as hepatic concentration of IL-1β and TNF-α to 56, 44, and 52%, respectively, as compared to TAA-control group.

Losartan treatment (5 mg/kg) significantly decreased hepatic tissue MPO activity as well as

	Parameters	MPO (U/g tissue)	IL-1β (pg/g tissue)	TNF-β (pg/100 mg tissue)
Groups	Normal Control	1.18 ± 0.07	7.39 ± 0.25	149.73 ± 5.55
	TAA-Control (300 mg/kg, i.p.)	12.49[a] ± 1.09	59.47[a] ± 2.76	571.80[a] ± 8.91
	TAA + Silymarin (100 mg/kg, p.o.)	6.93a,b ± 0.13	26.25[a,b] ± 1.54	297.26[a,b] ± 9.17
	TAA + Losartan (5 mg/kg, p.o.)	6.51[a,b] ± 0.24	36.1[a,b] ± 1.19	306.47[a,b] ± 3.94

Table 3. Effects of losartan (5 mg/kg) and silymarin (100 mg/kg) on hepatic tissue inflammatory parameters and cytokines; myloperoxidase (MPO), interleukin-1beta (IL-1β) and tumor necrosis factor-alpha (TNF-α); in thioacetamide-induced hepatic damage in rats. Rats of the normal control group received only saline. Hepatic damage was induced in the remaining 3 groups by single intraperitoneal injection of thioacetamide (TAA; 300 mg/kg). Group 2 received only thioacetamide (TAA; 300 mg/kg, i.p.) and served as TAA-control group. Groups 3 and 4 received TAA, followed by daily silymarin (100 mg/kg, p.o.) and losartan (5 mg/kg, p.o.) respectively for 30 days. All animals were sacrificed 24 h after the last treatment. The livers were removed, homogenized and the homogenate was obtained. Data is presented as mean ± SEM (n = 10). [a] Significantly different from normal control group at $p < 0.05$ (Tukey's post hoc test). [b] Significantly different from TAA-control group at $p < 0.05$ (Tukey's post hoc test).

hepatic concentration of IL-1β and TNF-α to 52, 61, and 54%, respectively, as compared to TAA-control group. The effects of losartan and silymarin at the selected doses were not significantly different ($P < 0.05$, Table 3).

Histopathological examination of hepatic tissues

Hepatic sections prepared from rat from the TAA-Control showed severe deterioration of the overall histopathological picture. Losartan and silymarin administration resulted in improvement in the hepatic histopathological picture (Fig. 1).

DISCUSSION

The present study was conducted to test the potential anti-oxidant and anti-inflammatory effects of losartan against thioacetamide-induced hepatic damage in rats.

Liver is considered the major site for metabolism in the body. It is also responsible for detoxification and elimination of exogenous drugs and other xenobiotics thus protecting the body from their destructive effects [39]. Liver's detoxification capacity along with other secretory functions decline significantly in liver damage exposing all body organs to severe toxicity [40]. Thioacetamide (TAA) is commonly used for induction of extensive liver damage in rats. The underlying mechanisms of action include profound elevation in reactive oxygen species (ROS) and nitric oxide metabolites (NOx) [12,41].

In the present work, intraperitoneal injection of TAA (300 mg/kg) in rats resulted in significant hepatic damage as manifested by significant disruption of serum liver function tests. Serum AST, ALT and ALP activities, total bilirubin concentration were significantly elevated whilst serum total protein concentration was significantly decreased indicating severe cellular damage. Hepatic tissue oxidative stress parameters; MDA and NOx metabolites were significantly elevated whilst hepatic tissue GSH was significantly decreased. Moreover, significant elevations in hepatic tissue inflammatory parameters; MPO, IL-1β and TNF-α were apparent when compared to normal control group. Severe histopathological changes such as marked architecture distortion and appearance of significant ongoing fibrosis & necrosis were reported post TAA administration.

Several data are in-line with our results [27,42-45]. These findings were mostly attributed to inflammation and oxidative stress damage. Ashkani-Esfahani *et al.* [46] reported significant elevation of serum liver function tests along with significant apoptosis, inflammatory cell infiltration, and centrilobular necrosis following TAA administration. Schemitt *et al.* [47] reported that acute TAA adminstration led to severe inflammaorty changes in rat livers as was manifested by severe elevation of hepatic tissue IL-1β, IL-6, IL-10, TNF-α and iNOS when compared to nor-

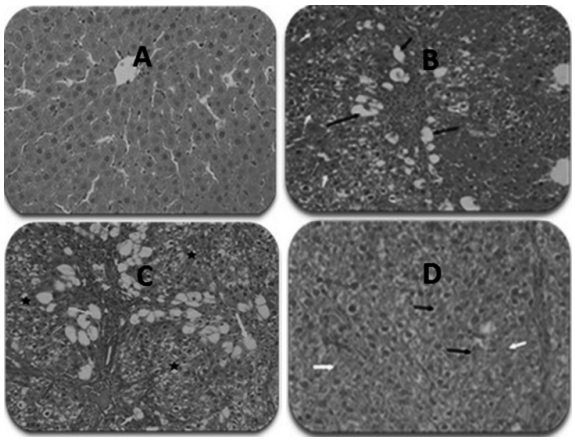

Figure 1. Histopathological examination of hepatic tissues. A) Photomicrograph of hepatic section prepared from a normal control rat; showing normal hepatic histopathological picture as manifested by plates of hepatocytes radiating from a central vein. These plates are separated by equal sized blood sinusoids (H&E X200). B) Photomicrograph of hepatic section prepared from a TAA-control rat; showing severely deteriorated histopathological picture manifested by marked architecture distortion, appearance of many pseudolobules, fibrosis and necrosis. Most hepatocytes appeared pyknotic. Karyolysis and karyorrhexis are also apparent (H&E X200). C). Photomicrograph of hepatic section prepared from a rat treated with silymarin (100 mg/kg, p.o.) for 30 days post TAA treatment; showing mild improvement of the overall hepatic histopathological picture. Fibrosis is slightly resolved; however, the fibrous tissue runs in septa between the nodules. (H&E X200). D) Photomicrograph of hepatic section prepared from a rat treated with losartan (5 mg/kg, p.o.) for 30 days post TAA treatment; showing improvement of the overall histopathological picture. Fibrosis and necrosis are significantly improved as demonstrated by arrows (H&E X200).

mal rats. Salama *et al.* [4] reported severe hepatic cirrhosis after TAA administration as was manifested by elevation of serum liver function tests as well as hepatic tissue concentrations of MDA, TNF-α and TGF-β. Moreover, the histopathology of hepatic tissues showed severe deterioration and this was further confirmed by immunohistochemistry of Bax, Bcl2 proteins and proliferating cell nuclear antigen.

Silymarin is a well-known hepato-protective agent used in treatment of different hepatic injuries [14]. Silymarin mainly exerts its actions via its anti-oxidant and anti-inflammatory properties [15]. In the present study, silymarin treated rats showed improvement of serum AST, ALT and ALP activities and total bilirubin concentration. Serum total protein concentration was significantly increased. Hepatic tissue oxidative stress parameters; MDA and NOx metabolites were significantly decreased whilst hepatic tissue GSH was significantly increased. Moreover, silymarin administration resulted in significant reduction in hepatic tissue inflammatory parameters; MPO, IL-1β and TNF-α. Histopathological picture was significantly improved when compared to TAA-control group.

Our data is in-line with many studies confirming the anti-oxidant and anti-inflammatory hepato-protective effects of silymarin [13,48-50].

Losartan is an AT_1R blocker commonly used in control of elevated arterial blood pressure. Losartan possesses protective effects in various experimental hepatic ischemia/reperfusion (I/R) models [18,19]. In the current study, losartan treated rats showed improvement of serum AST, ALT and ALP activities, and total bilirubin concentration. Serum total protein concentration was significantly increased. Hepatic tissue oxidative stress parameters; MDA and NOx metabolites were significantly decreased whilst hepatic tissue GSH was significantly increased. Moreover, losartan administration resulted in significant reduction in hepatic tissue inflammatory parameters; MPO, IL-1β and TNF-α. Histopathological picture was significantly improved when compared to TAA-control group. These results were comparable to those of silymarin.

In-line with our results, Wei *et al.* [21] reported that losartan stops advancement of the CCl_4-induced hepatic fibrosis. This was attributed to reduction in expression of AT_1R. Yokohama *et al.* [51] stated that treatment with losartan resulted in a significant reduction in serum AST and ALT activities as well as plasma TGF-β1 in patients suffering non-alcoholic steatohepatitis (NASH). The histopathological pictures of patients treated with losartan revealed huge improvement of hepatic fibrosis and inflammation. Ogata *et al.* [52] reported that losartan prevented HSCs proliferation and hepatic fibrosis in mice undergoing NASH induced by choline-deficient L-amino acid-defined diet. They postulated that losartan only suppressed hepatic fibrosis via suppression of TGF-β1.

However, our study is by far the first study to highlight the potential anti-oxidant and anti-inflammatory properties of losartan in modulation of TAA- induced hepatic damage in rats.

CONCLUSIONS

Losartan, an AT_1R blocker, exhibits potential hepato-protective properties against TAA-induced hepatic damage in rats. These effects can be attributed to its anti-oxidant and anti-inflammatory actions. The effects of losartan were found to be comparable to those of silymarin; a well-known hepato-protective agent used in treatment of hepatic injuries originating from various origins.

Funding. The study was financially supported by Taif University, Taif city, Kingdom of Saudi Arabia, grant No (1-438-5569).

REFERENCES

1. Alshawsh, M.A., M.A. Abdulla, S. Ismail & Z.A. Amin (2011) *Evid. Based Complement. Alternat. Med.* **2011**: 1-6
2. Kaplowitz, N. (2004) *Clin. Infect. Dis.* **38** (Supplement 2): S44-8.
3. O'connell, M. & S. Rushworth. (2008) *Br. J. Pharmacol.* **153**: 403-5.
4. Salama, S.M., M.A. Abdulla, A.S. AlRashdi, S. Ismail, S.S. Alkiyumi & S. Golbabapour (2013) *BMC Complement. Altern. Med.* **13**(1): 56.
5. Papa, S., C. Bubici, F. Zazzeroni & G. Franzoso (2009) *Biol. Chem.* **390**: 965-76.
6. Saleh, D.O., G.A.R. Abdel Jaleel, S.A. El-Awdan, F.Oraby & M. Badawi (2014) *Can. J. Physiol. Pharmacol.* **92**: 965-73.
7. Fang, Y.-Z., S. Yang & G. Wu. (2002) *Nutrition.* **18**: 872-9.
8. Saad, A.A., E.-H.M. Mokhamer, M.A.A. Mohsen & G.A. Fadaly (2014) *J. Exp. Integr. Med.* **4**(3): 181.
9. Kim, H.G., D.H. Yoon, W.H. Lee, S.K. Han, B. Shrestha, C.H. Kim, *et al.* (2007) *J. Ethnopharmacol.* **114**: 307-15.
10. Stehbens, W.E. (2003) *Exp. Mol. Pathol.* **75**: 265-76.
11. de David, C., G. Rodrigues, S. Bona, L. Meurer, J. González-Gallego, M.J. Tuñón, *et al.* (2011) *Toxicol. Pathol.* **39**: 949-57.
12. Sathyasaikumar, K., I. Swapna, P. Reddy, C.R. Murthy, A.D. Gupta, B. Senthilkumaran, *et al.* (2007) *Neurochem. Res.* **32**: 517-24.
13. Mostafa, R.E., H.F. Zaki, A.A. Sleem, O.M. Abdel-Salam, F.A. Morsy & S.A. Kenawy (2013) *Pharmacologia* **4**(3).
14. Lang, Q., Q. Liu, N. Xu, K.-L. Qian, J.-H. Qi, Y.-C. Sun, *et al.* (2011) *Biochem. Biophys. Res. Commun.* **409**: 448-53.
15. Oliyarnyk, O., I. Markova, H. Malinska, J. Trnovska, M. Huttl, V. Skop, *et al.* (2017) *Atherosclerosis* **263**: e44.
16 Ramasamy, K. & R. Agarwal (2008) *Cancer Lett.* **269**: 352-62.
17 Koh, E.J., S.J. Yoon & S.M. Lee (2013) *Br. J. Pharmacol.* **169**: 1404-16.
18 Suzuki, Y., M. Ruiz-Ortega, O. Lorenzo, M. Ruperez, V. Esteban & J. Egido (2003) *Int. J. Biochem. Cell Biol.* **35**: 881-900.
19 Guo, L., K.S. Richardson, L.M. Tucker, M.A. Doll, D.W. Hein & G.E. Arteel (2004) *Hepatology* **40**: 583-9.
20 Ramalho, F.S., I. Alfany-Fernandez, A. Casillas-Ramirez, M. Massip-Salcedo, A. Serafín, A. Rimola, *et al.* (2009) *J. Pharmacol. Exp. Ther.* **329**: 130-40.
21. Wei, H.-S., D.-G. Li, H.-M. Lu, Y.-T. Zhan, Z.-R. Wang, X. Huang, *et al.* (2000) *World J. Gastroenterol.* **6**(4): 540.
22. Schupp, M., J. Janke, R. Clasen, T. Unger & U. Kintscher (2004) *Circulation* **109**: 2054-7.
23. Horiuchi, M. & M. Mogi (2011) *Br. J. Pharmacol.* **163**: 1122-30.
24. Amano, Y., T. Yamaguchi, K. Ohno, T. Niimi, M. Orita, H. Sakashita, *et al.* (2012) *Hypertens. Res.* **35**: 715-9.
25. Pang, T., J. Benicky, J. Wang, M. Orecna, E. Sanchez-Lemus & J.M. Saavedra(2012) *J. Hypertens.* **30**: 87-96.
26. Goyal, S., S. Bharti, J. Bhatia, T. Nag, R. Ray & D. Arya (2011) *Diabetes Obes. Metab.* **13**: 533-41.
27. Mustafa, H.N., S.A. El Awdan & G.A. Hegazy (2013) *Tissue Cell.* **45**: 350-62.
28. Reitman, S. & S. Frankel (1957) *Am. J. Clin. Pathol.* **28**: 56-63.
29. Belfield, A. & D.M. Goldberg (1971) *Arch. Dis. Child.* **46**: 842-6.
30. Walters, M. I. & H. Gerarde (1970) *Microchem. J.* **15**: 231-43.
31. Gornall, A.G., C.J. Bardawill & M.M. David (1949) *J. Biol. Chem.* **177**: 751-66.
32. Beutler, E., O. Duron & B.M. Kelly (1963) *J. Lab. Clin. Med.* **61**: 882-8.
33. Uchiyama, M. & M. Mihara (1978) *Anal. Biochem.* **86**: 271-8.
34. Miranda, K.M., M.G. Espey & D.A. Wink (2001) *Nitric Oxide* **5**: 62-71.
35. Roelofs, J.J., K. M. Rouschop, J.C. Leemans, N. Claessen, A.M. de Boer, W.M. Frederiks, *et al.* (2006) *J. Am. Soc. Nephrol.* **17**: 131-40.
36. Moody, M.D., S.W. Van Arsdell, K.P. Murphy, S.F. Orencole & C. Burns (2001) *Biotechniques* **31**: 186-90, 92-4.
37. Brouckaert, P., C. Libert, B. Everaerdt, N. Takahashi, A. Cauwels & W. Fiers (1993) *Immunobiology* **187**: 317-29.
38. Bancroft, J., A. Stevens & D. Turner (1996) *Theory and practice of histological techniques.* 4th ed. New York: Churchill Livingston.

39. Saleem, T.M., C.M. Chetty, S. Ramkanth, V. Rajan, K.M. Kumar & K. Gauthaman (2010) *Int. J. Pharm. Sci. Res.* **1**: 1-5.
40. Abdelaziz, R.R., W.F. Elkashef & E. Said 2015) *Environ. Toxicol. Pharmacol.* **40**: 259-67.
41. Amirtharaj, G.J., S.K. Natarajan, A. Pulimood, K. Balasubramanian, A. Venkatraman & A. Ramachandran (2017) *Cardiovasc. Toxicol.* **17**: 175-84.
42. Omnia, M., M. Nabila & R. Nadia.(2014) *Benha Vet. Med. J.* **27**: 8-24.
43. Mostafa, R.E., A.A. Salama, R.F. Abdel-Rahman & H.A. Ogaly (2016) *Can. J. Physiol. Pharmacol.* **95**: 539-47.
44. Pawa, S. & S. Ali (2004) *Biochim. Biophys. Acta* **1688** (3): 210-22.
45. Kuramochi, M., T. Izawa, M. Pervin, A. Bondoc, M. Kuwamura & J. Yamate (2016) *J. Exp. Toxicol. Pathol.* **68**: 471-7.
46. Ashkani-Esfahani, S., F. Bagheri, Y. Emami, E. Esmaeilzadeh, N. Azarpira, N. Hassanabadi, *et al.* (2016) *Iran. Red Crescent Med. J.* **18**(8) e29166. doi: 10.5812/ircmj.29166.
47. Schemitt, E., J. Colares, R. Hartmann, F. Licks, M.D.C. Soares, J.D.O. Salvi, *et al.* (2016) *J. Hepatol.* **64**: S310.
48. Chen, I.S., Y.C. Chen, C.H. Chou, R.F. Chuang, L.Y. Sheen & C.H. Chiu (2012) *J. Sci. Food Agric.* **92**: 1441-7.
49. Vargas-Mendoza, N., E. Madrigal-Santillán, Á. Morales-González, J. Esquivel-Soto, C. Esquivel-Chirino, M.G.L. González-Rubio, *et al.* (2014) *World J. Hepatol.* **6**(3): 144.
50. Kabiri, N., M. Ahangar-Darabi, M. Setorki & M. Rafieian-Kopaei (2013) *J. Herb. Med. Pharmacol.* **2**: 29-33.
51. Yokohama, S., M. Yoneda, M. Haneda, S. Okamoto, M. Okada, K. Aso, *et al.* (2004) *Hepatology* **40**: 1222-5.
52. Ogata, H., H. Noguchi, T. Ohtsubo, J. Liao, H. Kohara, K. Yamada, *et al.* (2016) *Integr. Mol. Med.* **3**: 520-3.